

# Prostate urothelial carcinoma diagnosed on prostatic needle biopsy. Case report with literature overview

## Prostatos urotelio karcinoma, diagnozuota atlikus prostatos biopsiją. Klinikinis atvejis ir literatūros apžvalga

Algimantas Sruogis<sup>1</sup>, Ugnius Mickys<sup>2</sup>, Tadas Petraitis<sup>1</sup>, Edita Kaubrienė<sup>3</sup>, Feliksas Jankevičius<sup>1</sup>

<sup>1</sup> *Vilnius University Institute of Oncology, Urology Department, Santariškių str. 1, LT-08661 Vilnius, Lithuania*

<sup>2</sup> *Lithuanian National Centre of Pathology*

<sup>3</sup> *Vilnius University Institute of Oncology, Radiology Department*

*E-mail: sruogis@loc.lt*

<sup>1</sup> *Vilniaus universiteto Onkologijos instituto Urologijos skyrius, Santariškių g. 1, LT-08661 Vilnius*

<sup>2</sup> *Lietuvos nacionalinis patologijos centras*

<sup>3</sup> *Vilniaus universiteto Onkologijos instituto Intervencinės echoskopijos ir ultragarsinės diagnostikos skyrius*

*El. paštas: sruogis@loc.lt*

---

### Objective

To establish criteria for the diagnosis of primary urothelial prostate carcinoma after the differential diagnosis including high-grade urothelial carcinoma extending into the bladder neck and prostate versus poorly differentiated prostate adenocarcinoma extending into the bladder.

### Case report

The patient was a 37-year-old man with severe prostatism symptoms, who presented with an atypical seminal vesicles fluid cytological test result. The prostate was also normal by the digital examination, endoscopy, roentgenography, ultrasonography and serum markers. A diagnostic transurethral resection of bladder mucosa, bladder neck specimen revealed normal urothelial tissues. The urine cytological test result was negative. The transrectal biopsy of the prostate revealed an urothelial carcinoma with a negative staining of PSA (prostate-specific antigen) and positive of cytokeratins CK 8 and CK HMW. The patient subsequently underwent radical cystoprostatectomy and pelvic lymphadenectomy with ileal conduit m. Brycker creation. The histological diagnosis was the urothelial carcinoma of the prostate. Also, the prostate showed foci of High Grade PIN and prostate adenocarcinoma. After 15 months the patient has a PSA level of 0.2 ng/mL, no symptoms, no evidence of progression. Based on this case of the urothelial carcinoma of prostate, the

literature was reviewed and the morphological differentiation between urothelial carcinoma and adenocarcinoma of the prostate was discussed.

### Conclusions

The diagnostic criteria are the following: (1) the tumor should be a macro-, microscopically and immunohistochemically verified as urothelial carcinoma localized exclusively in the prostate gland; (2) there must be no other primary urothelial carcinoma in the body. These criteria can be readily applied when evaluating surgical resection specimens. With the use of radiologically guided or endoscopically derived biopsies, however, the pathologist is increasingly called upon to make a diagnosis before definitive surgical resection. In these circumstances, the pathologist will often resort to immunostains to help refine the differential diagnosis. Moreover, even when surgical resection specimens are evaluated, immunostains are still used in conjunction with histomorphology to confirm the diagnosis, particularly when a rare entity such as primary urothelial prostate carcinoma is encountered.

**Key words:** prostate cancer, urothelial carcinoma, prostate urothelial carcinoma, prostatic needle biopsy

### Tikslas

Nustatyti diagnostinius prostatos urotelio karcinomos kriterijus, diferencijuojant urotelio karcinomą, peraugančią šlapimo pūslės kaklelį ir prostatą, nuo prostatos adenokarcinomos, peraugančios šlapimo pūslę.

### Atvejis

Pacientas, 37 metų, trejus metus gydytas nuo lėtinio prostatito. Prostatos sekrete nustačius atipinių ląstelių, įtarus prostatos vėžį, ligonis nusiųstas į VU Onkologijos institutą. Tyrimo pro tiesiąją žarną, cistoskopijos, rentgenologinio, ultragarso ir serumo žymenų tyrimo duomenimis, didesnių pokyčių nerasta. Atlikus transuretrinę šlapimo pūslės gleivinės biopsiją (TUR) iš šlapimo pūslės sienelių, kaklelio ir šlaplės prostatinės gleivinės, histologiškai nustatyti normalūs urotelio audiniai. Šlapimo citologinis tyrimas buvo neigiamas. Atlikus transrektalinę prostatos biopsiją, diagnozuotas prostatos urotelio navikas, imunohistochemiškai neigiamas PSA (prostatos specifiniam antigeniui) ir teigiamas citokeratinams CK8 ir CK HMW. Pacientui buvo atlikta radikali cistoprostektomija, pašalinti dubens limfmazgiai ir suformuotas šlapimo nuotėkis į *ileum* segmentą, išvestą į priekinę pilvo sieną (*Brycker* būdu). Morfologinė diagnozė – prostatos urotelio karcinoma. Taip pat diagnozuota prostatos adenokarcinoma ir prostatos intraepitelinė neoplazija. Po 15 mėnesių PSA lygis buvo 0,2 ng/ml, jokių ligos progresavimo požymių nepasireiškė. Remiantis šiuo klinikiniu atveju straipsnyje apžvelgiama literatūra, aiškinantis prostatos urotelio karcinomos ir adenokarcinomos skirtumus.

### Išvados

Diagnozuojant prostatos urotelio karcinomą reikia vadovautis tam tikrais kriterijais: 1) prostatos urotelio karcinoma turi būti verifikuota makro-, mikroskopiškai ir imunohistocheminiais metodais, 2) neturėtų būti kitų urotelio karcinomos židinių organizme. Būtent prostatos biopsija leidžia patologui nustatyti tikslią diagnozę prieš operaciją. Imunohistocheminis tyrimas padeda atlikti diferencinę diagnostiką. Po operacijos tiriant pašalintus audinius, diagnozė patikslinama histomorfologiškai, naudojant imunohistocheminius tyrimus, net jei ir labai retai nustatoma prostatos urotelio karcinoma.

**Reikšminiai žodžiai:** prostatos vėžys, urotelio karcinoma, prostatos urotelio karcinoma, prostatos biopsija

### Introduction

No data exist on urothelial carcinoma diagnosed on prostatic needle biopsy. In the literature, we found only 21 cases of urothelial carcinoma diagnosed on prostate needle biopsy from 1991 to 1998 in Department of Pathology, Johns Hopkins Hospital, Bal-

timore, Maryland, USA [1]. The diagnosis of urothelial carcinoma on prostate needle biopsy is difficult, because it is rare and clinically can mimic prostatic adenocarcinoma; often there is no history of urothelial carcinoma elsewhere.

## Case report

The patient was a 27-year-old man with severe prostatism symptoms, who presented with an atypical seminal vesicles fluid cytological test result. The prostate was also normal by the digital examination, endoscopy, roentgenography, ultrasonography and serum markers. Octant biopsy of the prostate revealed 2/8 urothelial carcinoma spread in the prostate tissue. The diagnostic transurethral resection of bladder mucosa, bladder neck specimen revealed normal urothelial tissues. Octant biopsy of the prostate revealed 2/8 urothelial carcinoma spread in the prostate tissue. The patient subsequently underwent radical cystoprostatectomy and pelvic lymphadenectomy with ileal conduit m. Brycker creation. The patient tolerated the procedure well and was discharged home on hospital day 11. The cystoprostatectomy specimen and associated lymph nodes were fixed in 10% buffered formalin, routinely processed, and embedded in paraffin. The sections were stained with haematoxylin-eosin and a variety of immunohistochemical markers, including prostate-specific antigen (PSA) and cytokeratins CK 8 and CK HMW. The histological diagnosis was a pure type of primary urothelial carcinoma of the prostate.

## Pathology

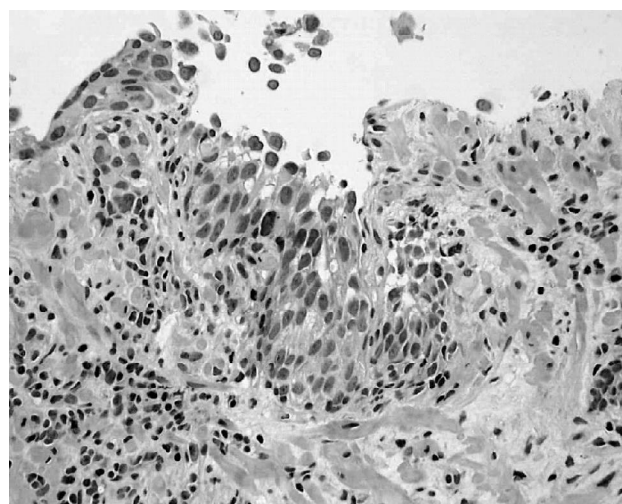
- 22 11 2002 2002/1/24739 octant biopsy of prostate: 2/8 urothelial carcinoma spread in prostate tissue (Fig.1).
- 02 12 2002 02/7/20960 cytology: Degenerating urothelial cells with nuclear atypia.
- 02 12 2002 02/1/25434 TUR: chronic active inflammation in fibrous tissue. Urothelial lining is absent.
- 16 01 2003 03/1/1055 Cystoprostatectomy: Poorly differentiated (high grade) urothelial carcinoma of prostatic urethra with spread to the prostate (Figs. 2, 3, 4, 5), seminal vesicle and the resection margin of the seminiferous duct (Figs. 6, 7). TNM (2002): pT2. Extensive urothelial carcinoma *in situ* in urinary bladder mucosa (Fig. 8). Moderately differentiated adenocarcinoma of

prostate, Gleason 3 + 3 = 6, spreading 5% of the prostate in both lobes (Figs. 3, 4, 5). TNM (2002): pT2c. High grade PIN (Fig. 9). Urachus cyst in the muscular wall of the urinary bladder.

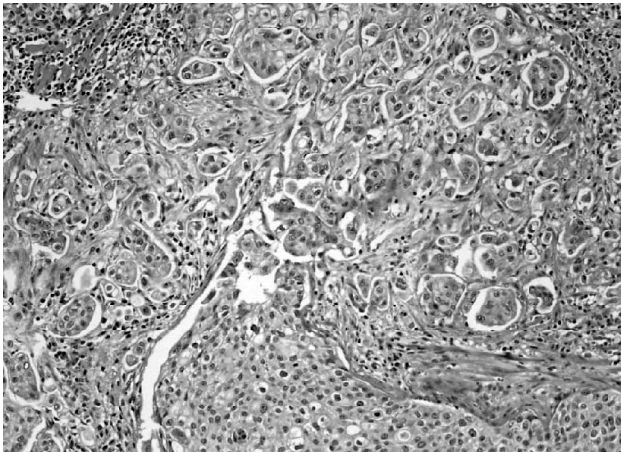
## Discussion

### Classification

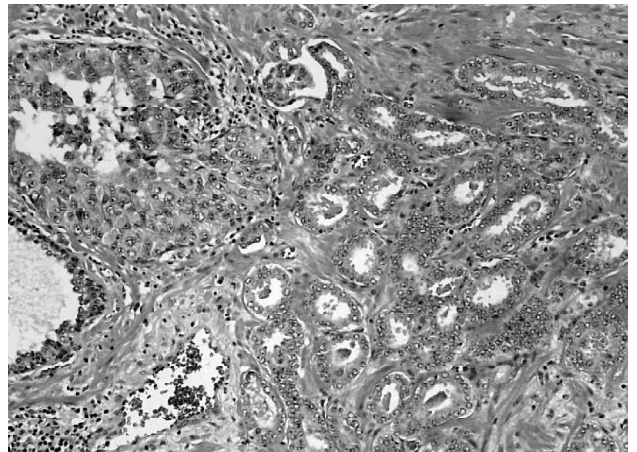
In the updated comprehensive classification, urothelial carcinoma (TCC) of the prostate is presented in accordance with the current nomenclature which is based mainly on the theory of the multifocal origin of urothelial neoplasm's TCC of the prostate, and is classified as primary, secondary (synchronous and metachronous) or mixed (TCC associated with adenocarcinoma) [1]. Case histories of six patients with TCC of the prostate are presented in this study. One patient had primary TCC of the prostate without evidence of urothelial carcinoma elsewhere; another patient had primary mixed TCC associated with separate foci of adenocarcinoma; and four patients had secondary TCC either synchronously or metachronously with carcinoma foci elsewhere in the urothelium. The importance of considering TCC of the prostate as a well-defined clinicopathological entity is discussed.



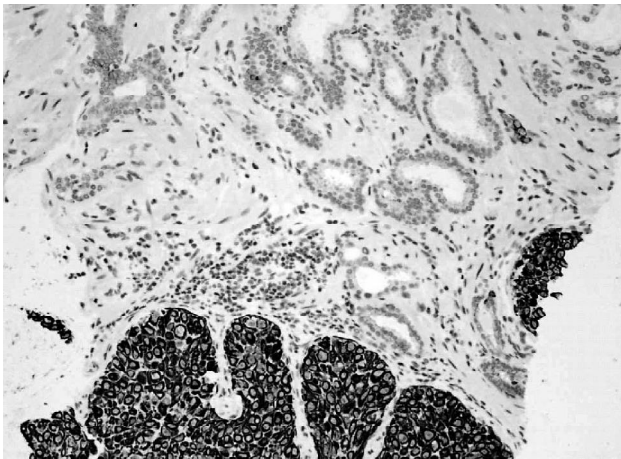
**Fig. 1.** HE 200x. Biopsy: Irregular large acinar structure, lined with atypical urothelium with small invasive nest in prostatic stroma



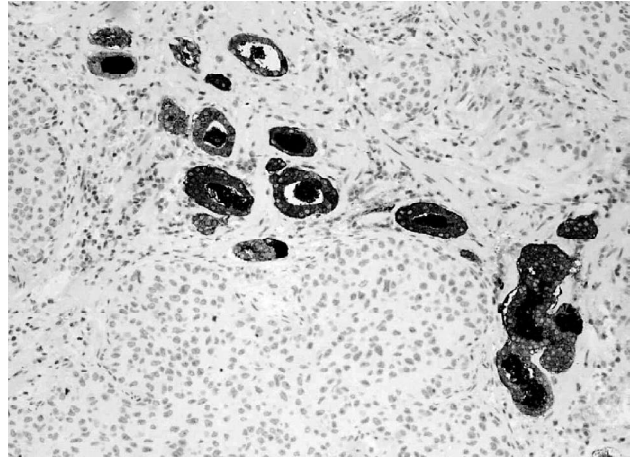
**Fig. 2.** HE 100×. Nests of invasive poorly differentiated urothelial carcinoma in prostatic stroma



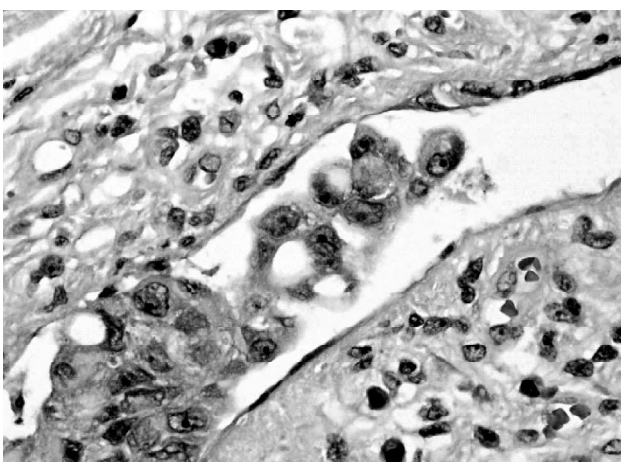
**Fig. 3.** HE 200×. Invasive poorly differentiated urothelial carcinoma nest (upper left corner) and moderately differentiated adenocarcinoma of prostate (lower right corner)



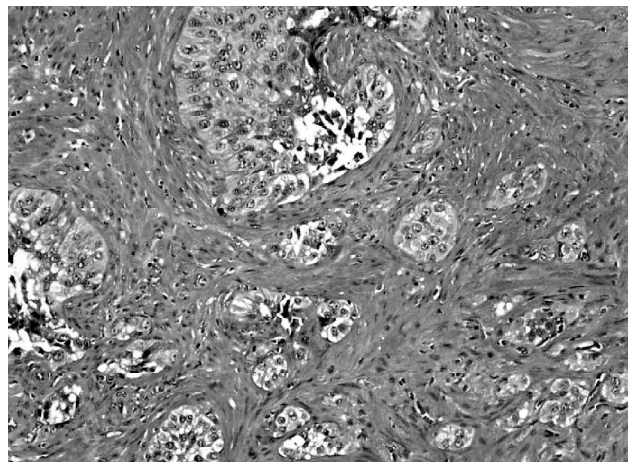
**Fig. 4.** Immunohistochemistry: urothelial carcinoma HMW-CK (+) (bottom), adenocarcinoma of prostate HMW-CK (-)



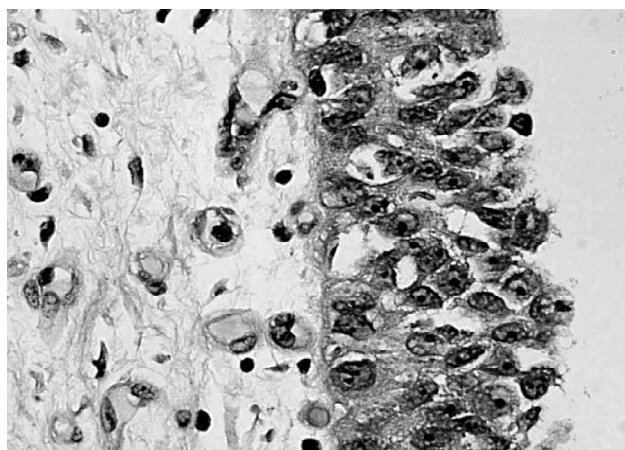
**Fig. 5.** Immunohistochemistry: PSA (+) prostate adenocarcinoma glands and completely PSA (-) urothelial carcinoma nests below



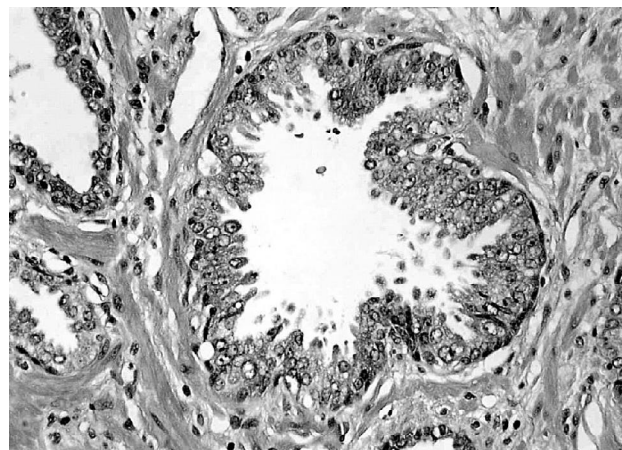
**Fig. 6.** HE 400×. Intravascular invasion of urothelial carcinoma



**Fig. 7.** HE 100×. Spread of urothelial carcinoma to seminal vesicle mucosa and muscular layer



**Fig. 8.** HE 400x. Ca *in situ* in urothelium of urinary bladder: macro-nucleoli and nucleomegaly are prominent



**Fig. 9.** HE 200x. High-grade PIN in prostate

### Survival

Algaba et al. presented 5 cases which represented 1.5% of a series of 323 consecutive prostatic carcinomas [3]. Cases with possible tumours as well as those tumours of a transitional pattern that contain prostatic acid phosphatase in the cellular cytoplasm were ruled out to make the diagnosis. The mean age of the tumoral onset was 70 years with symptomatology identical to that of adenocarcinoma. In 20% of cases it is associated with an adenocarcinoma and in 40% with a bladder carcinoma without contiguity. The mean survival is 10.6 months with 60% succumbing within the first 6 months.

Oliai et al. reported nine cases of urothelial carcinoma of the prostate [1]. Six of the nine (67%) patients with DCIS eventually died of the disease (DOD) (2 with prior urothelial cell carcinoma, 1 with no prior or subsequent history, 3 without information), and 3 of 9 (33%) patients with DCIS were alive with a residual disease (AWD). Of the patients with invasive carcinomas, 4 of 8 (50%) were DOD, 2 of 8 (25%) were AWD, and 2 of 8 (25%) were alive without evidence of disease. All men who are alive were treated aggressively with surgery and often adjuvant chemotherapy-radiation. Overall, 10 of 17 (59%) men were DOD with a mean survival of 23.2 months (2–72 months) after diagnosis.

Njinou et al. reviewed the degree to which extension from urothelial carcinoma into the prostate af-

fects the survival [3]. They also compared whether prostatic stromal invasion occurring via direct extension through the bladder wall differs from stromal invasion arising intraurethrally. A total of 76 men who underwent radical cystectomy for urothelial carcinoma also had prostate involvement. The patients were separated into group 1 – 18 patients with primary bladder tumour extending transmurally through the bladder wall to invade the prostate, and group 2 – 58 patients with prostate involvement arising from within the prostatic urethra. In the latter group, the degree of prostate invasion was classified as urethral mucosal involvement, ductal/acinar involvement and stromal invasion. The 5-year overall survival and recurrence-free rate were 22% and 28% in group 1 *versus* 43% and 45% in group 2, respectively. In group 2, the survival rates were similar to those with prostatic urethral and ductal tumours (without stromal invasion). The five-year overall survival rates without and with stromal invasion were 49% and 25%, respectively ( $p = 0.024$ ). Prostate involvement decreased the survival, which varied according to primary bladder stages (Pis, PI, P2a/b and P3a/b,  $p = 0.004$ ) or superficial (Pis, Pa and PI) and muscle invasive (P2a/b and P3/b,  $p = 0.045$ ) disease in two groups. Those with positive lymph nodes experienced poorer outcomes in both groups. The 5-year overall survival rate in 19 men with positive lymph nodes was 13%, and it was 44% with negative lymph nodes ( $p = 0.034$ ). The major

prognostic factors were age, the degree of prostate invasion and lymph node involvement. They concluded that invasion pathways of prostate in patients with urothelial bladder carcinoma have a statistically significant prognostic role in survival. Urothelial carcinoma of the bladder, extending into the prostate through the bladder wall, and bladder carcinoma that did not directly infiltrate the prostate through the bladder wall are two different clinicopathological entities that should not be included in the same staging grade.

### *Differential diagnosis*

The differential diagnosis includes high-grade urothelial carcinoma extending into the bladder neck and prostate *versus* poorly differentiated prostate adenocarcinoma extending into the bladder [3]. Since both tumours can present with similar high-grade histological and nuclear features, distinction by haematoxylin-eosin alone can be difficult. The difference is of clinical value as well, since the distinction alters both therapy and cancer staging. In these situations, immunohistochemical stains may help distinguish one origin from the other [3, 5–9]. For instance, carcinoma in the bladder neck area was definitively attributed to urothelial origin, since the foci with prostatic extension stained for CK7 and CK20 but not PSA, PAP, or CD57. This staining pattern exactly matches that of the urothelial primary tumour, confirming extension from the bladder. In fact, in this case, the distinction is particularly salient since the patient has both a urothelial and prostatic primary tumour, and either could extend into the bladder neck. Indeed, this same diagnostic dilemma has been addressed in recent literature.

In a study by Lindeman and Weidner [10], the investigators stained 29 prostate adenocarcinomas, 31 urothelial tumours, and 5 “poorly differentiated carcinomas of uncertain type” with a battery of immunostains, including CK7, CK20, PSA, PAP, and CEA, among others. All the tumours of “uncertain origin” were located in the junction of the bladder neck and prostate and could be attributed to either prostatic or urothelial origin. Each was stained for PSA, PAP, and CK7. Of the 5 tumours, 1 stained for PSA and PAP

only, consistent with prostatic origin, another stained for CK7 only, consistent with urothelial origin, and the remaining 3 showed overlapping features, staining for all 3 markers. The authors attributed this finding to the “overlapping features” of the urothelial and prostate tissue, since both are embryologically derived from the urogenital sinus, explaining that, as such, some tumours cannot be definitively classified into either category. The immunohistochemical panel used by Lindeman and Weidner is similar to that proposed by Genega et al. [11]. In their recent study of 73 prostate tumours and 46 urothelial tumours, the authors suggest using a panel of six markers to distinguish between the two types. The markers include PSA, PAP, 34βE12, Leu-7, CK7, and p53. They did not, however, deem polyclonal CEA, CK20, B72.3, or Leu-M1 to be sensitive or specific enough to reliably distinguish between the two.

In summary, the use of immunohistochemical stains can be an integral part of differentiating high-grade urothelial carcinoma from prostate carcinoma, particularly when the two tumours are in close proximity, with overlapping histological features. As illustrated, a panel of stains used in combination appears to be the most useful diagnostic tool [6–10]. Obviously, immunohistochemical staining is a valuable tool for assessing all types of collision tumours, from both the genitourinary tract and other organ systems.

Prostatic adenocarcinoma and urothelial carcinoma (urothelial carcinoma) may coexist in the prostate. However, no carcinoma with mixed features has been recognized. The intraductal carcinoma with urothelial carcinoma areas usually merged with regions of prostatic adenocarcinoma with a papillary or cribriform pattern. Urothelial carcinoma features are usually associated with ductal carcinoma of high stage. Areas of prostatic adenocarcinoma with urothelial carcinoma features should be considered histopathologically as areas of mixed carcinoma of the prostate. Prostatic adenocarcinoma with areas of urothelial carcinoma features may pose a difficult differential diagnosis problem with urothelial carcinoma, especially with small biopsies with a weak focal immunoreactivity for PAP, PSA, and thrombomodulin.

Prostatic urothelial carcinoma concomitant with a bladder tumour is rare, but its incidence is increasing

due to the precision of histological examination and the prevalence of bladder carcinoma *in situ*. Its prognosis depends on the depth of the prostatic lesion: carcinoma *in situ*, involvement of the ducts or even the stroma. In the case of high grade bladder tumour, multifocal tumour or bladder carcinoma *in situ*, a transurethral resection of the prostate is the best way of detecting this lesion. The therapeutic options depend on the depth of the prostatic invasion.

### Markers

Based on a review of the literature [6–10], urothelial carcinoma might be mCEA<sup>+</sup>, but certainly CK7<sup>+</sup>, CK20<sup>+</sup>, PSA<sup>-</sup>, PAP<sup>-</sup>, and CD57<sup>-</sup>. The prostate carcinoma might be PSA<sup>+</sup>, PAP<sup>+</sup>, CD57<sup>+</sup>, mCEA<sup>-</sup>, CK7<sup>-</sup>, and CK20<sup>-</sup>. Interestingly, the urothelial tumour was indeed CK7<sup>+</sup>, but also both CK20<sup>+</sup> and CD57<sup>+</sup>. However, there was a striking staining difference between CK20 and CD57. Only the superficial, better-differentiated papillary component stained for CK20 [7], whereas only the deeper, infiltrative component stained for CD57. Some authors postulated that the CD57<sup>+</sup> component represented either a more poorly differentiated focus or a neuroendocrine subtype. However, failure to stain with chromogranin, synaptophysin, and neuron-specific enolase made neuroendocrine differentiation unlikely [12]. Favouring a poorly differentiated disease, poorly differentiated urothelial

carcinoma has been shown to stain only weakly for CK20. Additionally, staining for mCEA was so weak and focal compared with the strongly diffuse staining for CK7 that the stain was largely non-contributory. However, as expected, prostate carcinoma was positive for PSA, PAP, and CD57, and no prostate tissue stained for mCEA, CK7, or CK20.

### Treatment

Although the prognosis is poor even with only apparent DCIS, histologic recognition is essential, because the only possibility of improved outcome is early and aggressive treatment [1]. Radical cystoprostatectomy is the pure type of primary urothelial carcinoma of the prostate [3].

### Conclusions

We established the criteria for the diagnosis of primary urothelial prostate carcinoma after differential diagnosis including high-grade urothelial carcinoma extending into the bladder neck and prostate versus poorly differentiated prostate adenocarcinoma extending into the bladder. The criteria are the following: (1) the tumour should be a macro-, microscopically and immunohistochemically verified urothelial carcinoma, localized exclusively in the prostate gland; (2) there must be no other primary urothelial carcinoma in the body. These criteria can be readily applied when eva-

**Table 1.** Immunohistochemical staining of the primary urothelial and prostate carcinomas, urothelial extension into the prostate, and lymph node with metastatic tumour

Variable	PSA	PAP	CK7	CK20	CD57	mCEA
Urothelial carcinoma	-	-	+ diffuse	+ papillary component only	+ infiltrative component only	+ weakly positive, scant, focal staining
Prostate adenocarcinoma	+	+	-	-	+	-
Urothelial extension into prostate	-	-	+	+	-	NA
Lymph node (metastatic tumours)	+ focal	+ focal	+	+ focal	+	NA

PSA indicates prostate-specific antigen; PAP – prostatic acid phosphatase; CK7 – cytokeratin7; CK20 – cytokeratin 20; CD 57 anti-Leu-7 monoclonal antibody; mCEA – monoclonal carcinoembryonic antigen; and NA – not applicable

luating surgical resection specimens. With the use of radiologically guided or endoscopically derived biopsies, however, the pathologist is increasingly called upon to make a diagnosis before definitive surgical resection. In these circumstances, the pathologist will often resort to immunostains to help refine the

differential diagnosis. Moreover, even when surgical resection specimens are evaluated, immunostains are still used in conjunction with histomorphology to confirm the diagnosis, particularly when a rare entity such as primary urothelial prostate carcinoma is encountered.

## REFERENCES

1. Oliyai BR, Kahane H, Epstein JI. A clinicopathologic analysis of urothelial carcinomas diagnosed on prostate needle biopsy. *Am J Surg Pathol* 2001 Jun; 25(6): 794–801.
2. Schujman E, Mukamel E, Slutzker D, Mor C, Servadio C. Prostatic urothelial carcinoma: concept of its pathogenesis and classification. *Isr J Med Sci* 1983 Sep; 19(9): 794–800.
3. Algaba F, Santaularia JM, Lamas M, Ayala G. Transitional cell carcinoma of the prostate. *Eur Urol* 1985; 11(2): 87–90.
4. Lorge F, Moulin P, Jamart J, Van Cangh PJ. Transitional cell carcinoma involving the prostate: a clinicopathological retrospective study of 76 cases. *J Urol* 2003 Jan; 169(1): 149–152.
5. Ergen A, Balbay M, Irwin M, Torno R. Collision metastasis of bladder and prostate carcinoma to a single pelvic lymph node. *Int Urol Nephrol* 1995; 27: 743–745.
6. Wang N, Zee S, Zarbo R, Bacchi C, Gown A. Coordinate expression of cytokeratins 7 and 20 defines subsets of carcinomas. *Appl Immunohistochem* 1995; 3: 99–107.
7. Chu P, Wu E, Weiss L. Cytokeratin 7 and cytokeratin 20 expression in epithelial neoplasms: a survey of 435 cases. *Mod Pathol* 2000; 13: 962–972.
8. Sauvageot J, Epstein J. Immunoreactivity for prostate-specific antigen and prostatic acid phosphatase in adenocarcinoma of the prostate: relation to progression following radical prostatectomy. *Prostate* 1998; 34: 29–33.
9. May E, Perentes E. Anti-Leu 7 immunoreactivity with human tumors: its value in the diagnosis of prostatic adenocarcinoma. *Histopathology* 1987; 11: 295–304.
10. Lindeman N, Weidner N. Immunohistochemical profile of prostatic and urothelial carcinoma: impact of heat-induced epitope retrieval and presentation of tumors with intermediate features. *Appl Immunohistochem* 1996; 4: 264–275.
11. Genega EM, Hutchinson B, Reuter VE, Gaudin PB. Immunophenotype of high-grade prostatic adenocarcinoma and urothelial carcinoma. *Mod Pathol* 2000; 13: 1186–1191.
12. Iczkowski K, Shanks J, and Allsbrook W, et al. Small cell carcinoma of the urinary bladder is differentiated from urothelial carcinoma by chromogranin expression, absence of CD 44 variant 6 expression, a unique pattern of cytokeratin expression, and more intense  $\delta$ -enolase expression. *Histopathology* 1999; 35: 150–156.

*Gauta: 2005 07 10*

*Priimta spaudai: 2005 09 30*