

From Memory Impairment to Two Occluders in the Heart – A Multidisciplinary Case Report

A. Wiśniewski*

K. Filipka**

A. Ekkert***

**Department of Neurology,
Faculty of Medicine, Nicolaus
Copernicus University in Toruń,
Collegium Medicum in Bydgoszcz,
Poland*

***Department of Neurological
and Neurosurgical Nursing,
Faculty of Health Sciences,
Nicolaus Copernicus University
in Toruń, Collegium Medicum
in Bydgoszcz, Poland*

****Centre of Neurology, Vilnius
University, Lithuania*

Summary. Transient global amnesia (TGA) is a rare cause of a sudden onset of confusion and anterograde amnesia. It is considered of ischemic, epileptogenic, or venous origin. The etiology is uncertain, although hypertension, hyperlipidemia, and ischemic heart disease are considered as possible mechanisms. The impact of stress, migraine, physical effort is also highlighted. In contrast to ischemic stroke, atrial fibrillation (AF) and patent foramen ovale (PFO) are relatively rarely reported in the pathophysiology of acute memory impairment. In most cases, no visible lesion is detected on neuroimaging. This case report presents a 62-year-old woman with TGA symptoms who had an acute left temporal lobe ischemic lesion confirmed by diffusion-weighted imaging sequence of magnetic resonance imaging. Extensive workup revealed coexistence of AF and PFO. Due to intolerance to oral anticoagulants, percutaneous closure of left atrial appendage and PFO was performed within two months. Combined heart interventions have proven to be a safe and efficient therapeutic option for secondary stroke prevention in this patient. This case illustrates that patients with sudden memory impairment require careful observation and extensive workup, as well as a multidisciplinary approach and treatment.

Keywords: transient global amnesia, stroke, patent foramen ovale, atrial fibrillation, percutaneous occlusion.

PREFACE

Transient global amnesia (TGA) is a rare cause of a sudden onset of memory disturbances, confusion, anterograde amnesia, accompanied by repetitive questioning, which usually resolves in 24 hours [1]. The Hodges and Warlow criteria are used for the recognition of TGA [2]. The exact mechanism is still undetermined, although various hypotheses have been made, including ischemic, epileptic, or venous origin [3, 4]. Migraine, physical effort, and stress are highlighted as common risk factors [5, 6].

Usually, TGA is characterized by a low recurrence rate, absence of brain lesions on neuroimaging, and is linked to

hypertension, hyperlipidemia, and ischemic heart disease [7–10]. While the role of atrial fibrillation (AF) and patent foramen ovale (PFO) in stroke is hard to overestimate, the significance of cerebral embolic events in TGA has not yet been established [10, 11]. The patient should be observed in the hospital until the memory deficit resolves. However, an extensive workup for TGA is not currently recommended because the outcome is favourable and no specific therapy is indicated [12].

We present the case of a patient with clinical symptoms of TGA for whom extensive diagnostics revealed coexisting AF and PFO requiring two percutaneous interventions.

DESCRIPTION OF THE CASE

A 62-years old female with a history of hypertension and hyperthyroidism was admitted to hospital because of disorientation and loss of memory that occurred immediately

Address:

*Adam Wiśniewski, MD, PhD
Department of Neurology, The University Hospital No. 1,
Collegium Medicum, Nicolaus Copernicus University
Skłodowskiej St. 9, 85-094 Bydgoszcz, Poland
Email: adam.lek@wp.pl*

© Neurologijos seminarai, 2021. Open Access. This article is distributed under the terms of the Creative Commons Attribution 4.0 International License CC-BY 4.0 (<http://creativecommons.org/licenses/by/4.0/>), which permits unrestricted use, distribution, and reproduction in any medium, provided you give appropriate credit to the original author(s) and the source, provide a link to the Creative Commons license, and indicate if changes were made.

after waking up. She could not remember the events of the previous day and asked her family members the same questions repeatedly. The initial neurological examination, otherwise unremarkable, revealed anterograde amnesia. The patient was conscious, fully oriented in time, place and person. Computed tomography scan of the head did not show any acute findings. There were also no significant abnormalities in laboratory blood tests. The patient was admitted to the department of neurology with a preliminary diagnosis of transient global amnesia. Magnetic resonance imaging (MRI), performed the next day, revealed a small focus of restricted diffusion (3–4 mm) medially from the temporal horn of the lateral ventricle (Fig. 1).

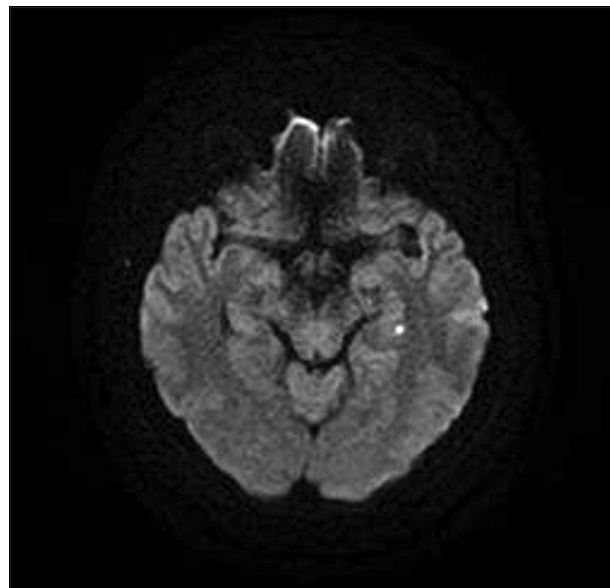


Fig. 1. Acute ischemic lesion in the left hemisphere (diffusion-weighted imaging sequence of magnetic resonance imaging)

The diagnosis of acute ischemic stroke was confirmed. Subsequent 24-hour Holter monitoring revealed AF paroxysms lasting up to 7.3 sec. (Fig. 2).

Contrast-enhanced transcranial Doppler ultrasound (c-TCD) revealed no high-intensity transient signals at rest. Nevertheless, after the Valsalva maneuver, multiple signals were registered leading to the diagnosis of a moder-

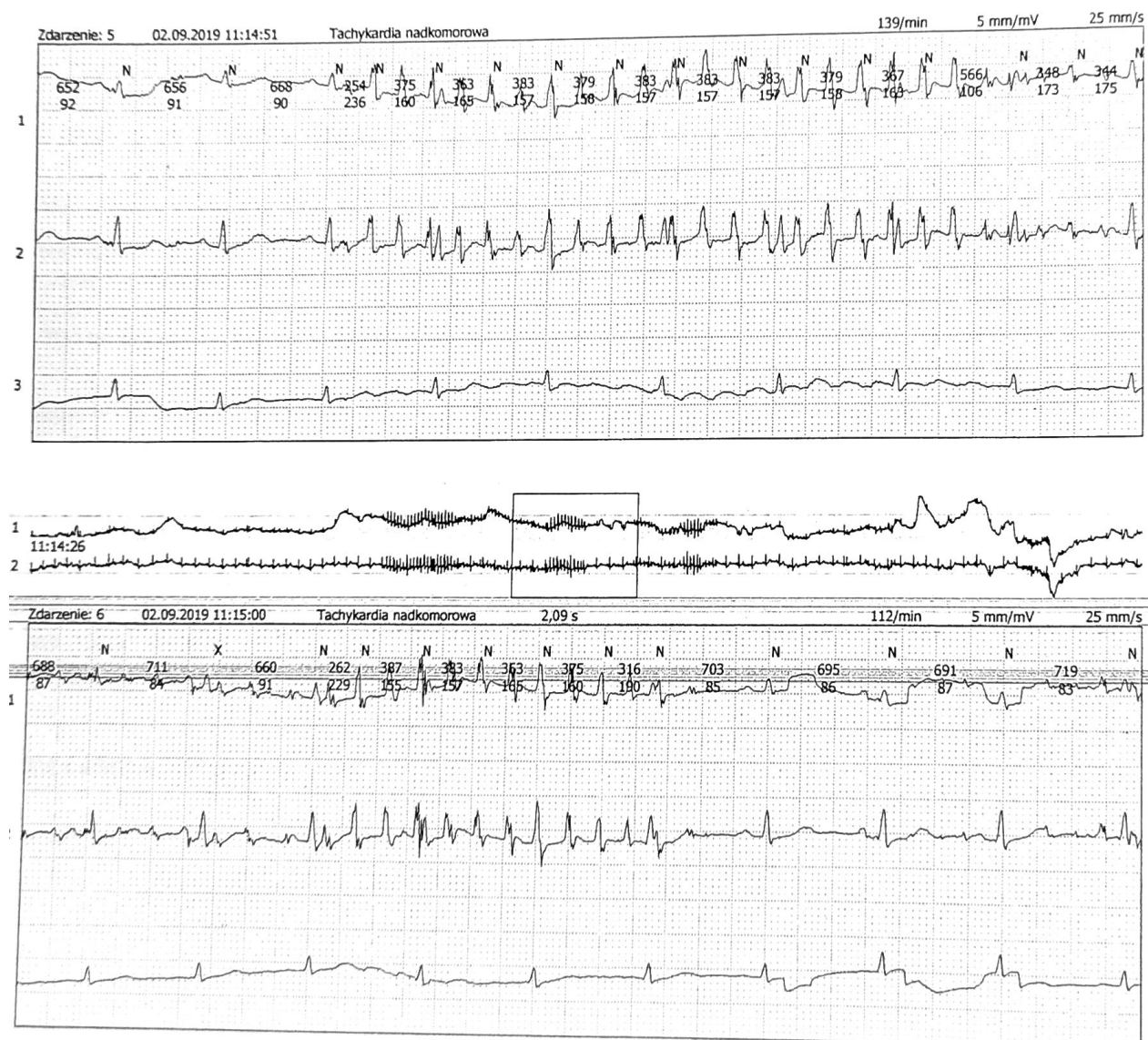


Fig. 2. Detection of AF by Holter electrocardiography monitoring (24 hours)

ate right-to-left shunt. This finding was confirmed by subsequent contrast-enhanced transesophageal echocardiography (TEE). On discharge, oral anticoagulant therapy with dabigatran was recommended. TEE examination a month later also revealed a patent foramen ovale with a contrast leak from the right to the left atrium. The patient was qualified for percutaneous PFO closure, however, the risk of paradoxical embolism (total Risk of Paradoxical Embolism (RoPE) score 5) in the course of PFO was moderate. Taking into account the patient's higher risk of thromboembolic complications (CHA₂DS₂-VASc- 4 points), moderate risk of bleeding (HAS-BLED 2 points) and dabigatran intolerance (skin changes, dyspepsy, malaise), percutaneous closure of the left atrium appendage (LAA) with the Watchman occluder was performed prior to the PFO closure procedure, followed by dual antiplatelet therapy. Two months later, percutaneous PFO closure with Figulla Flex PFO23/25 occluder was performed, after which dual antiplatelet therapy was recommended for six months. Control echocardiography two months later confirmed the correct position of the PFO and LAA occluders. No signs of shunt, LAA residual flow, or thrombi were detected.

DISCUSSION

Brain ischemia is considered the main cause of acute memory impairment [9]. Usually, it does not lead to necrosis of the brain, and therefore, in most cases, no visible ischemic changes are found on neuroimaging. However, 22% of patients have lesions in DWI sequence of MRI, which is equivalent to the diagnosis of acute ischemic stroke [13]. Moreover, visible DWI lesions are associated with a higher risk of recurrent course of TGA (estimated at 2.9–26.3%) [14]. Taking into account only the clinical manifestation, at first it could seem that the presented case would be a typical TGA, and the patient should be discharged after resolution of the symptoms with no further workup, according to the recommendations [12].

However, the case illustrates the need for an in-depth neurological and cardiological assessment when dealing with patients presenting with memory impairment. As we can see, two risk factors for a possible disabling stroke in the future were identified by thorough investigations.

Anticoagulation was mostly important in relation to AF, as the RoPE score was moderate [15]. In accordance with the updated guidelines for stroke management, dabigatran, a new oral anticoagulant, was used for secondary prevention of stroke [16]. In most cases, new oral anticoagulants are sufficient and do not cause adverse effects. However, our patient reported side effects of the drug, which are seen in 10–30% of subjects during therapy [17]. This was an indication to discontinue oral treatment and perform percutaneous surgery. LAA occlusion has been presented as a noninferior, effective, and safe therapeutic option for patients with nonvalvular atrial fibrillation [18]. It is still debatable whether in this particular case it was

necessary to first try to switch to another anticoagulant and only then make a decision on interventional treatment [19]. The indication for PFO closure in our patient is also controversial, as we cannot claim for sure that it was not an incidental finding with no significant contribution to the particular event [20, 21]. Some authors suggest that a combination of left atrial appendage closure and PFO closure may be a relevant choice to prevent recurrent ischemic stroke and protect the patient against other thrombotic complications in the future [22]. Sporadic cases described in the literature, where both procedures were performed in a short period of time, provide some data on the clinical course of ischemic stroke patients after such interventions [23–25]. However, there is insufficient data to draw conclusions about the risks and benefits.

The described case required a multidisciplinary approach and modification of the treatment method due to unexpected circumstances. In our opinion, the final result of the treatment should be considered satisfactory, as the extended workup revealed major risk factors for stroke which otherwise would be neglected, possibly resulting in repeated cardioembolic events in the future. We recommend individualizing the approach to patients with acute memory impairment, because, as presented in this case, it may be related to the causes that require interventional treatment.

References

1. Spiegel DR, McCroskey AL, Deyerle BA. A case of transient global amnesia. A review and how it may shed further insight into the neurobiology of delusions. *Innov Clin Neurosc* 2016; 13(3–4): 32–41.
2. Hodges JR, Warlow CP. Syndromes of transient amnesia: towards a classification. A study of 153 cases. *J Neurol Neurosurg Psychiatry* 1990; 53: 834–43. <https://doi.org/10.1136/jnnp.53.10.834>
3. Baracchini C, Tonello S, Farina F, et al. Jugular veins in transient global amnesia: innocent bystanders. *Stroke* 2012; 43: 2289–92. <https://doi.org/10.1161/STROKEAHA.112.654087>
4. Lanzone J, Ricci L, Assenza G, et al. Transient epileptic and global amnesia: real-life differential diagnosis. *Epilepsy Behav* 2018; 88: 205–11. <https://doi.org/10.1016/j.yebeh.2018.07.015>
5. Ness F, Griebel M, Ebert A, et al. Implicit learning in transient global amnesia and the role of stress. *Front Behav Neurosci* 2016; 10: 222. <https://doi.org/10.3389/fnbeh.2016.00222>
6. Jäger T, Szabo K, Griebel M, et al. Selective disruption of hippocampus-mediated recognition memory processes after episodes of transient global amnesia. *Neuropsychologia* 2009; 47: 70–6. <https://doi.org/10.1016/j.neuropsychologia.2008.08.019>
7. Quinette P, Guillery-Girard B, Dayan J, et al. What does transient global amnesia really mean? Review of the literature and thorough study of 142 cases. *Brain* 2006; 129: 1640–58. <https://doi.org/10.1093/brain/awl105>
8. Lee HY, Kim JH, Weon YC, et al. Diffusion-weighted imaging in transient global amnesia exposes the CA1 region of the hippocampus. *Neuroradiology* 2007; 49: 481–7. <https://doi.org/10.1007/s00234-007-0213-5>

9. Yang Y, Kim S, Kim JH. Ischemic evidence of transient global amnesia: location of the lesion in the hippocampus. *J Clin Neurol* 2008; 4: 59–66. <https://doi.org/10.3988/jcn.2008.4.2.59>
10. Pantoni L, Bertini E, Lamassa M, et al. Clinical features, risk factors, and prognosis in transient global amnesia: a follow-up study. *Eur J Neurol* 2005; 12: 350–6. <https://doi.org/10.1111/j.1468-1331.2004.00982.x>
11. Spiegel DR, Smith J, Wade RR, et al. Transient global amnesia – current perspectives. *Neuropsychiatr Dis Treat* 2017; 13: 2691–703. <https://doi.org/10.2147/NDT.S130710>
12. Michel P, Beaud V, Eskandari A, et al. Ischemic amnesia: causes and outcome. *Stroke* 2017; 48: 2270–3. <https://doi.org/10.1161/STROKEAHA.117.017420>
13. Alessandro L, Calandri IL, Suarez MF, et al. Transient global amnesia: clinical features and prognostic factors suggesting recurrence. *Arq Neuropsiquiatr* 2019; 77(1): 3–9. <https://doi.org/10.1590/0004-282x20180157>
14. Auyeung M, Tsoi MH, Cheung CM, et al. Association of diffusion weighted imaging abnormalities and recurrence in transient global amnesia. *J Clin Neurosci* 2011; 18: P531–4. <https://doi.org/10.1016/j.jocn.2010.08.019>
15. Wessler BS, Kent DM, Thaler DE, et al. The RoPE Score and right-to-left shunt severity by transcranial Doppler in the CODICIA study. *Cerebrovasc Dis* 2015; 40: 52–8. <https://doi.org/10.1159/000430998>
16. Powers WJ, Rabinstein AA, Ackerson T, et al. Guidelines for the early management of patients with acute ischemic stroke: a guideline for healthcare professionals from the American Heart Association/American Stroke Association. *Stroke* 2018; 49: e46–99. <https://doi.org/10.1161/STR.000000000000158>
17. Dos Santos SM, Harder S. Benefit-risk assessment of dabigatran in the treatment of stroke prevention in non-valvular atrial fibrillation. *Drug Saf* 2014; 35: 295–307. <https://doi.org/10.1007/s40264-014-0151-1>
18. Kjeld T, Joergensen TS, Fornitz G, et al. Patent foramen ovale and atrial fibrillation as causes of cryptogenic stroke: is treatment with surgery superior to device closure and anticoagulation? A review of the literature. *Acta Radiol Open* 2018; 7: 2058460118793922. <https://doi.org/10.1177/2058460118793922>
19. Baker C, Dhamane AD, Rajpura J, et al. Switching to another oral anticoagulant and drug discontinuation among elderly patients with nonvalvular atrial fibrillation treated with different direct oral anticoagulants. *Clin Appl Thromb Hemost* 2019; 25: 1076029619870249. <https://doi.org/10.1177/1076029619870249>
20. Carroll JD, Saver JL, Thaler DE, et al. Closure of patent foramen ovale versus medical therapy after cryptogenic stroke. *N Engl J Med* 2013; 368: 1092–100. <https://doi.org/10.1056/NEJMoa1301440>
21. Furlan AJ, Reisman M, Massaro J, et al. Closure or medical therapy for cryptogenic stroke with patent foramen ovale. *N Engl J Med* 2012; 366: 991–9. <https://doi.org/10.1056/NEJMoa1009639>
22. Alushi B, Biasco L, Orzan F, et al. Patent foramen ovale treatment strategy: an Italian large prospective study. *J Cardiovasc Med* 2014; 15: 761–8. <https://doi.org/10.2459/JCM.000000000000138>
23. Nadel J, Subbiah R, Jacobs N, et al. Successful left atrial appendage closure in a patient with prior patent foramen ovale occlusion. *HeartRhythm Case Rep* 2019; 5: 183–6. <https://doi.org/10.1016/j.hrccr.2018.11.018>
24. Heersink D, Murdoch D, Humphries J, et al. Left atrial appendage closure device implantation after percutaneous atrial septal defect closure. *J Am Coll Cardiol Cardiovasc Interv* 2016; 9: e95–6. <https://doi.org/10.1016/j.jcin.2016.02.019>
25. Yu J, Liu X, Zhou J, et al. Long-term safety and efficacy of combined percutaneous LAA and PFO/ASD closure: a single-center experience (LAAC combined PFO/ASD closure). *Exp Rev Med Dev* 2019; 16: 429–35. <https://doi.org/10.1080/17434440.2019.1604216>

A. Wiśniewski, K. Filipka, A. Ekkert

NUO ATMINTIES SUTRIKIMO IKI DVIEJŲ OKLUZIJŲ ŠIRDYJE – DAUGIADISCIPLINIS ATVEJO APRAŠYMAS

Santrauka

Praeinančioji globalinė amnezija (PGA) – staigiu atminties sutrikimu ir sumišimu pasireiškiantis sindromas, kurio tiksliai etiologija nėra aiški. Tarp potencialių etiologinių veiksnių išvardijami smegenų išemija, epilepsinis aktyvumas arba veninės kraujotakos sutrikimai, nustatytos sąsajos su hipertenzija, hiperlipidemija ir koronarine širdies liga, minima streso, migrenos ir didelio fizinio krūvio įtaka. Prieširdžių virpėjimo (PV) ir atviros ovaliosios angos (AOA) įtaka PGA atveju, skirtingai nuo smegenų infarkto, aprašoma retai. Atlikus galvos smegenų neurovizualinius tyrimus, židinių pakitimų dažniausiai nenustatoma. Šiame straipsnyje aprašoma klinikinį atvejį, kai 62 metų pacientei, atvykusiai dėl PGA simptomų, atlikus galvos smegenų magnetinio rezonanso tomografiją difuzijos režimu, buvo nustatytas ūminės išemijos židiny kairiojoje smilkininėje skiltyje. Išsamesnio ištyrimo metu aptikti PV ir AOA. Dėl geriamųjų antikoagulantų netoleravimo buvo atliktas kairiojo prieširdžio ausytės uždarymas, praėjus dviem mėnesiams – AOA uždarymas. Šis atvejis parodo, kad pacientai, atvykstantys dėl staigaus atminties sutrikimo, turėtų būti tiriami išsamiau, įtraukiant multidisciplininę komandą į ištyrimo ir gydymo procesą.

Raktažodžiai: praeinančioji globalinė amnezija, insultas, atvira ovalioji anga, prieširdžių virpėjimas, kairiojo prieširdžio ausytės uždarymas.

Gauta:
2021 06 16

Priimta spaudai:
2021 06 30